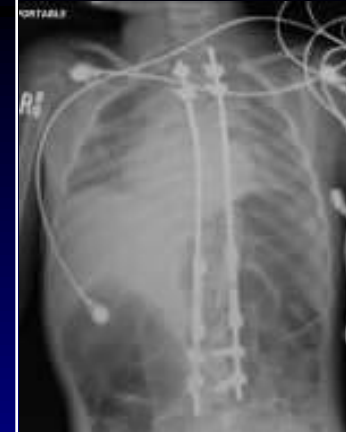
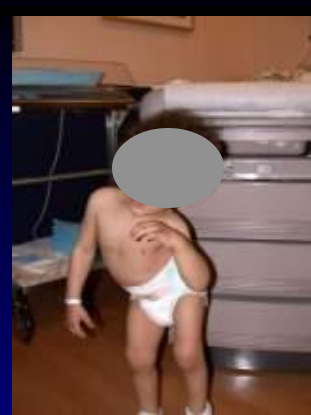


Early Onset Scoliosis *The Unsolved Challenge*

Michael G. Vitale MD MPH

**Chief, Pediatric Spine and Scoliosis Service
Associate Chief, Division of Pediatric Orthopaedic Surgery
Ana Lucia Associate Professor of Orthopaedic Surgery
Childrens Hospital Of New York; Columbia University Medical Center**



Morgan Stanley
Children's Hospital of New York-Presbyterian
Columbia University Medical Center

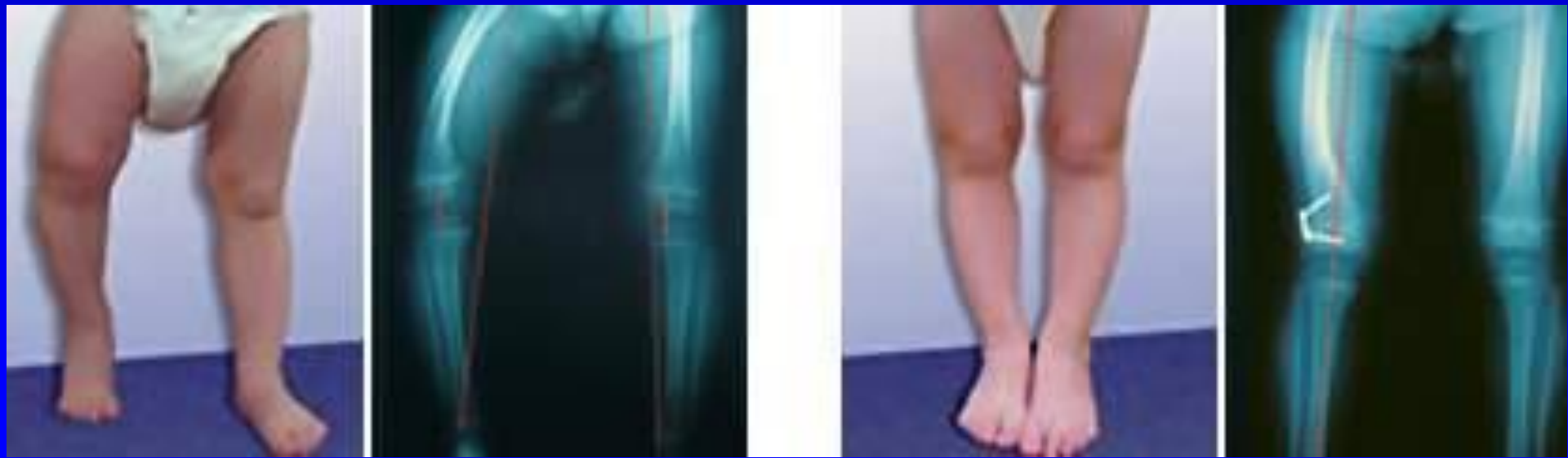

Columbia Orthopaedics
Pediatric Orthopaedic Surgery

**Controlling Scoliosis is good
but prevention would be
better....**

Growth Modulation

If we can staple the proximal tibial physis effectively for Blounts, can we staple the spine in scoliosis?

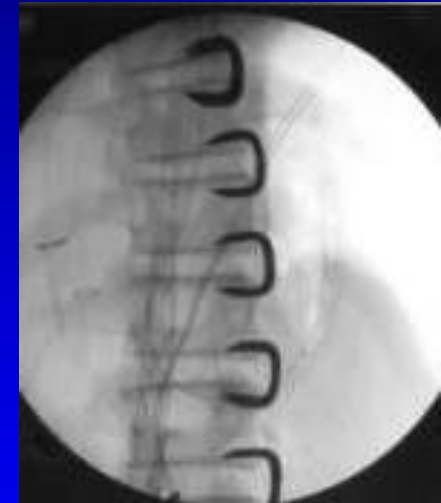

Vertebral Body Stapling

Vertebral Body Stapling Procedure for the Treatment of Scoliosis in the Growing Child

Randal R. Betz MD; Linda P. D'Andrea, MD; M. J. Mulcahey, MS; and Ross S. Chafetz, DPT

Betz et al, Clin Orthop 2005



An Innovative Technique of Vertebral Body Stapling for the Treatment of Patients With Adolescent Idiopathic Scoliosis: A Feasibility, Safety, and Utility Study

Randal R. Betz, MD,* John Kim, MD,† Linda P. D'Andrea, MD,* M. J. Mulcahey, MS,* Rohinton K. Balsara, MD,‡ and David H. Clements, MD§

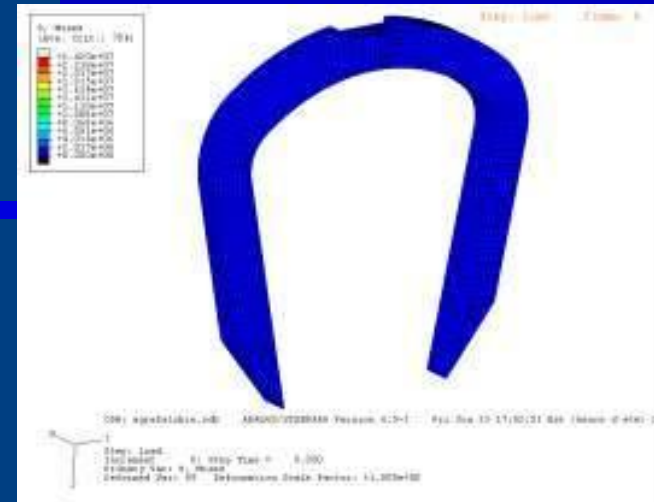

Betz et al, Spine 2003

Temperature-Sensitive, Shape Memory Alloy Staple

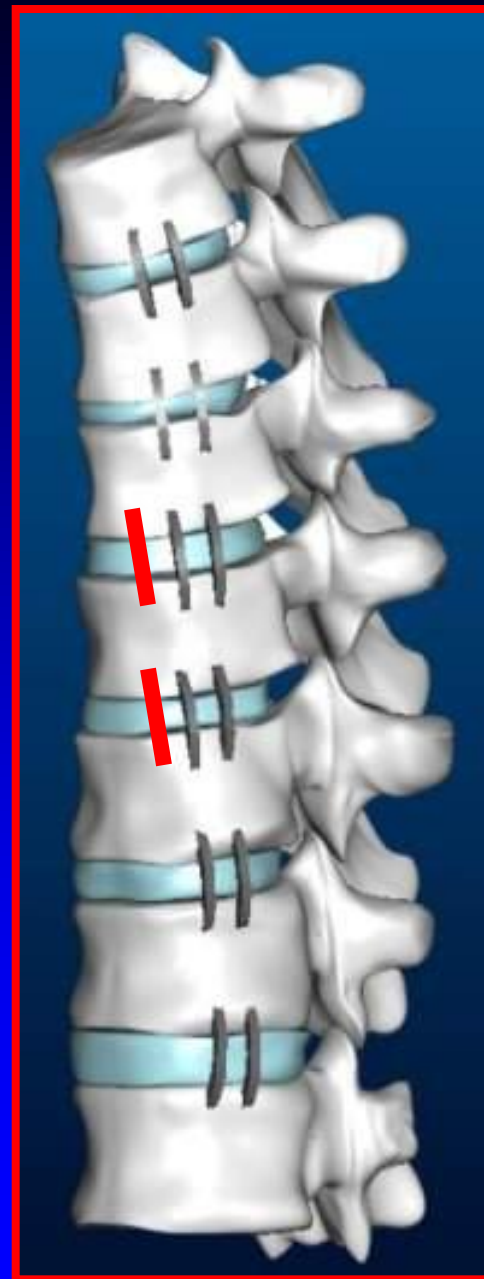
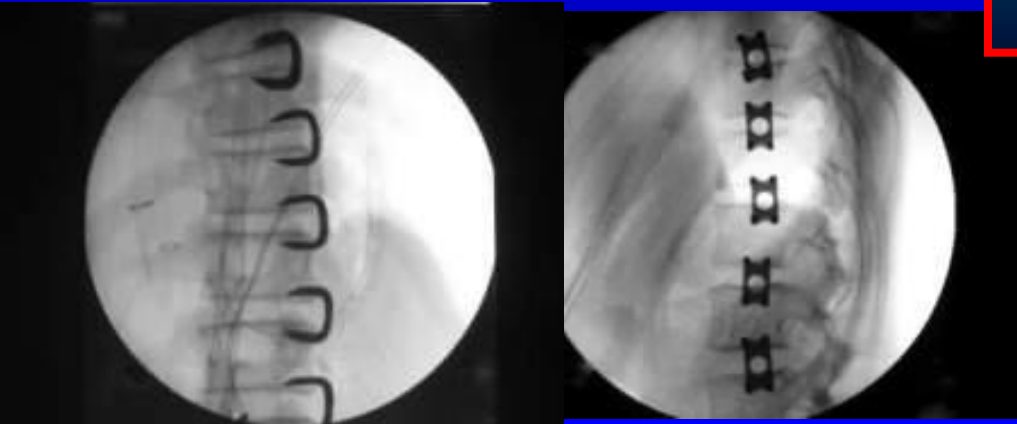
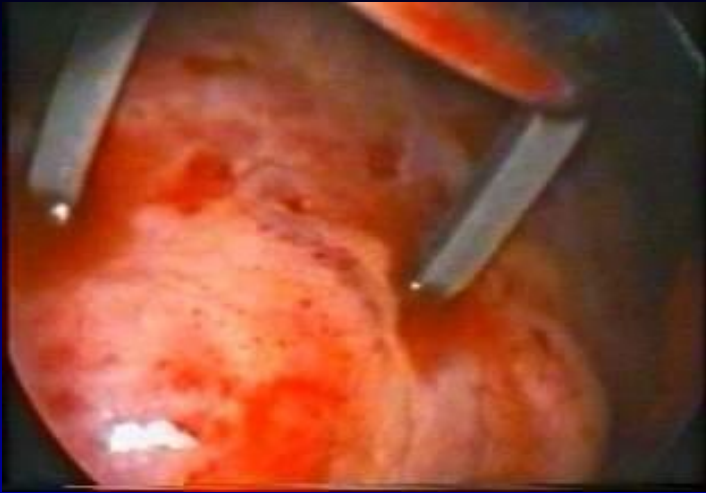
NITINOL

Nickel-**T**itanium-**N**aval-**O**rdnance-**L**aboratory

- 50% Nickel, 50% Titanium
- Improved pullout
- Constant force after implantation



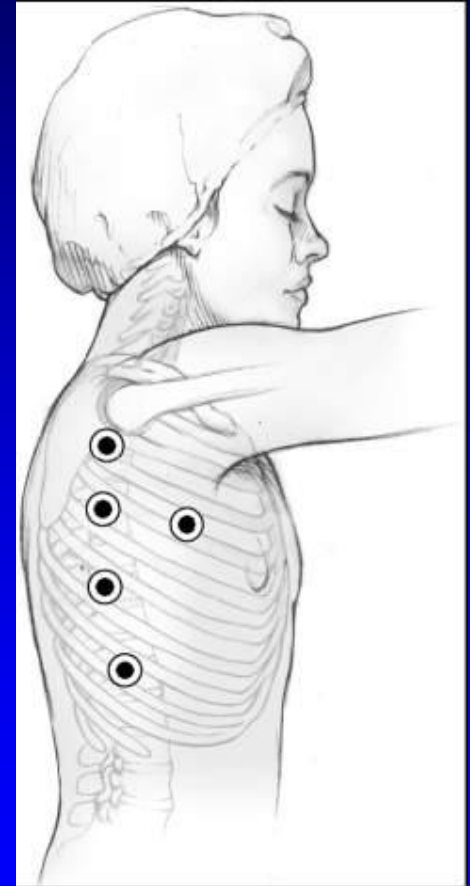Courtesy Randy Betz



Courtesy Randy Betz

Surgical Technique

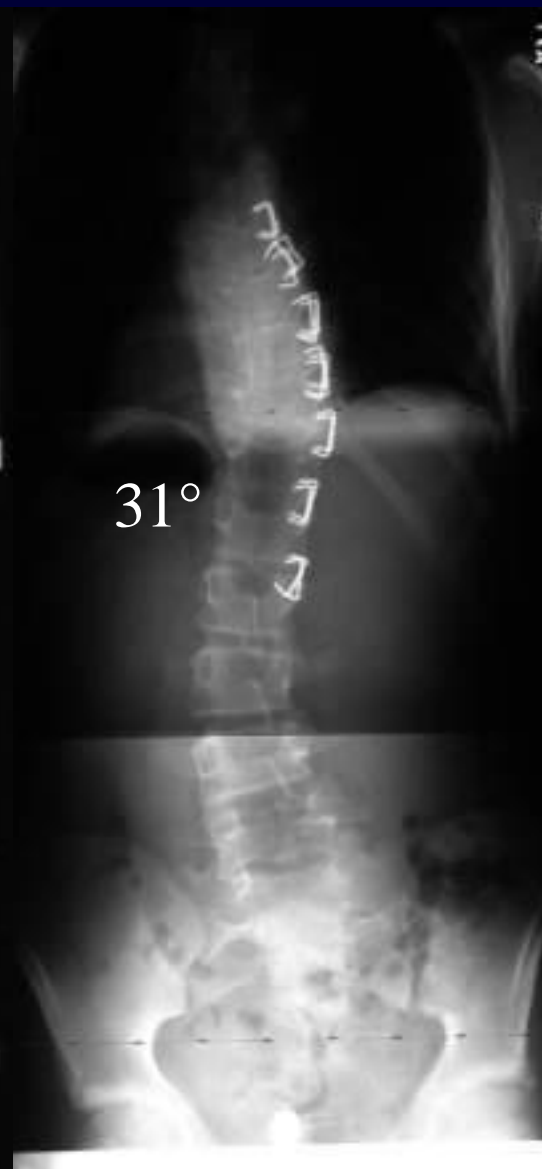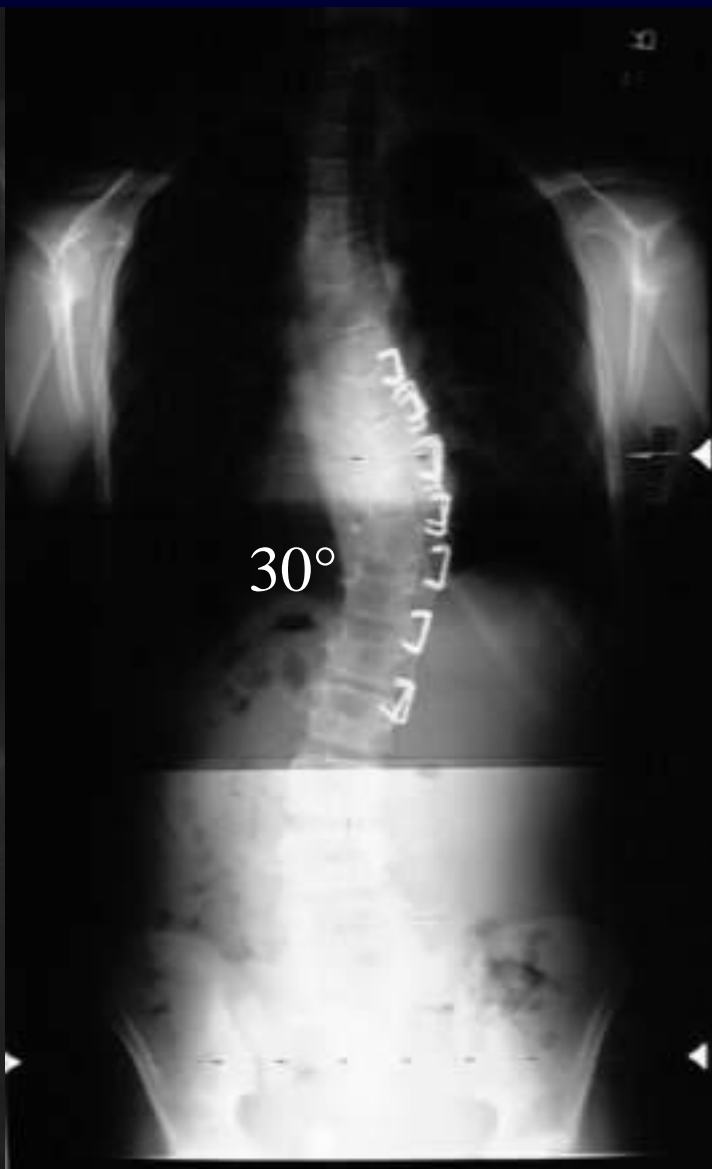
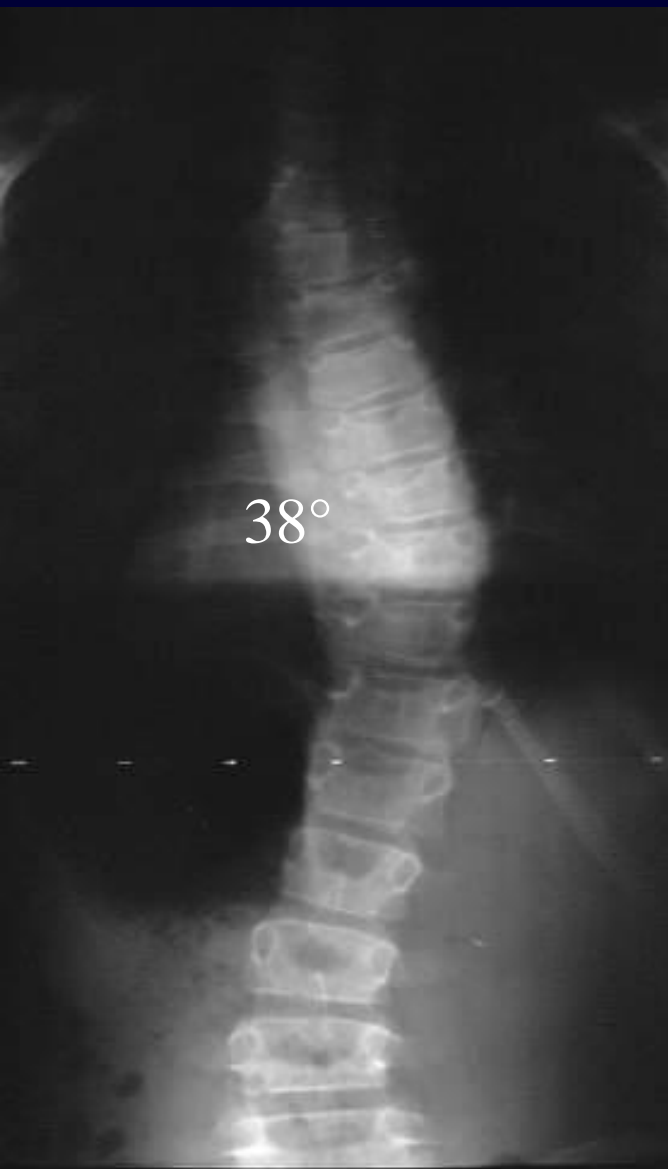- Thoracoscopic assisted surgery
- Double lumen endotracheal tube
- Trial inserter to size staple and create pilot holes
- Insert chilled staple
- Anterior placement to prevent lordosis
- Post op chest tube



Pre

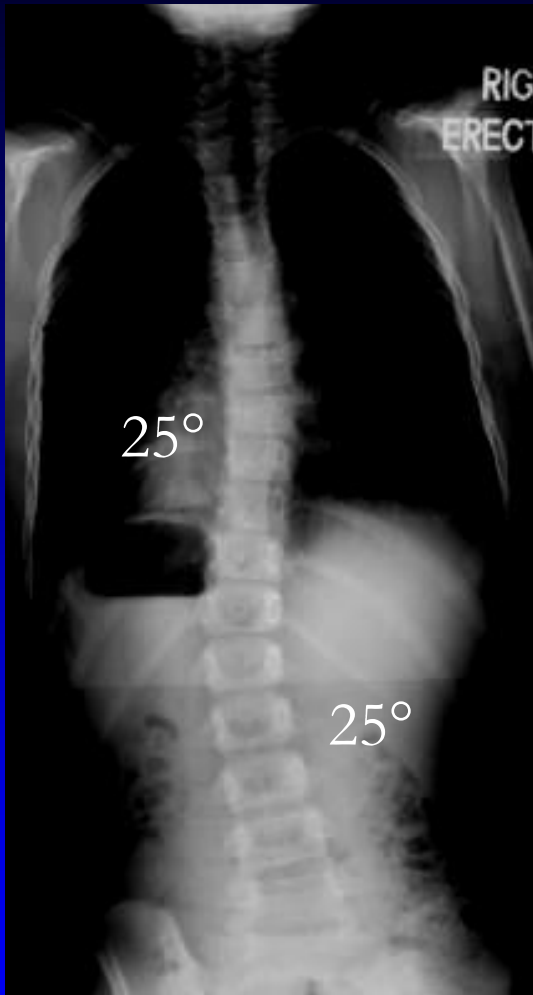12 mo

54 mo

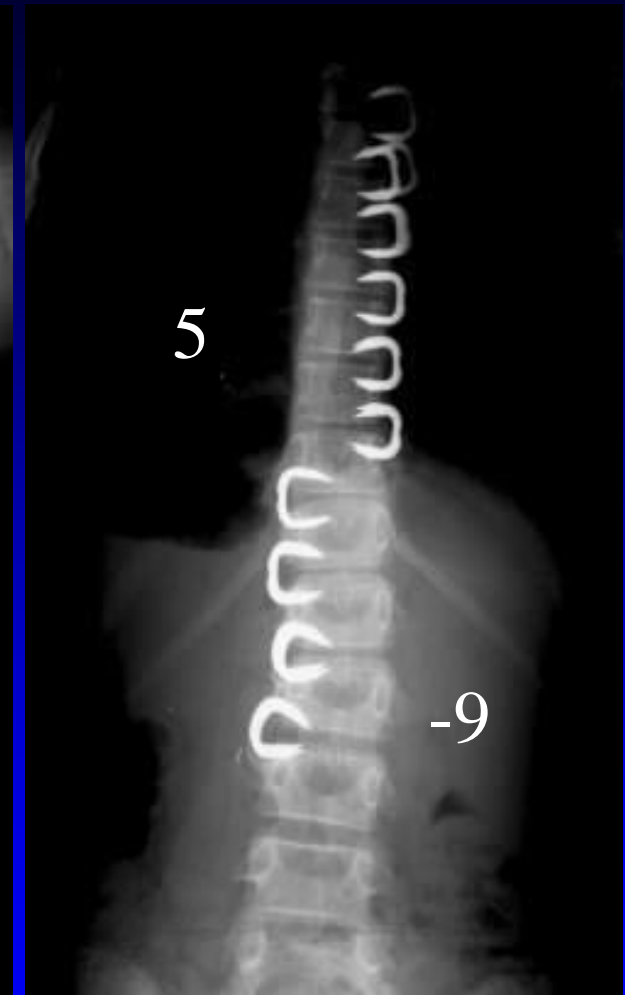
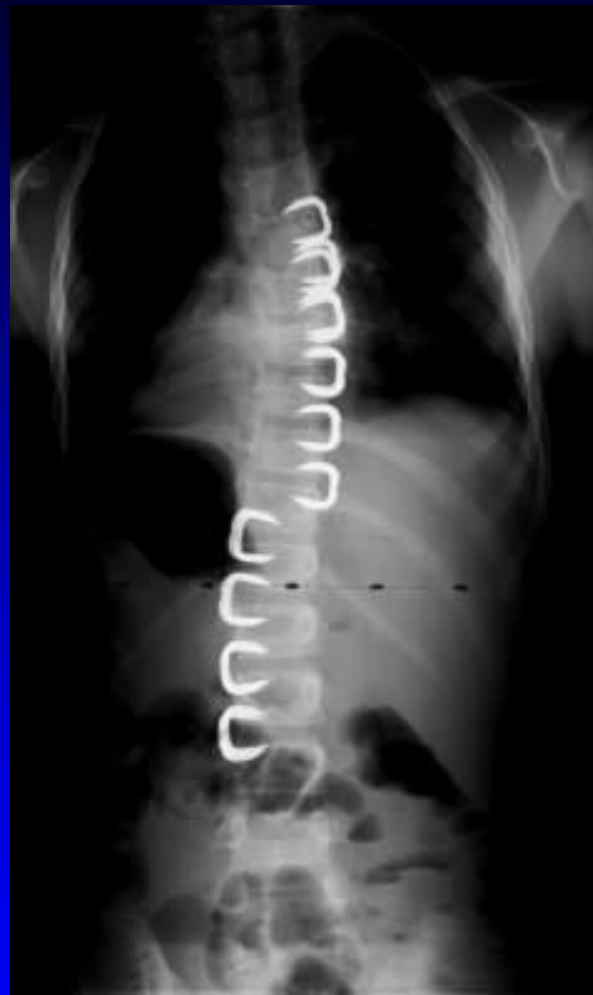

I'm interested

Courtesy Randy Betz



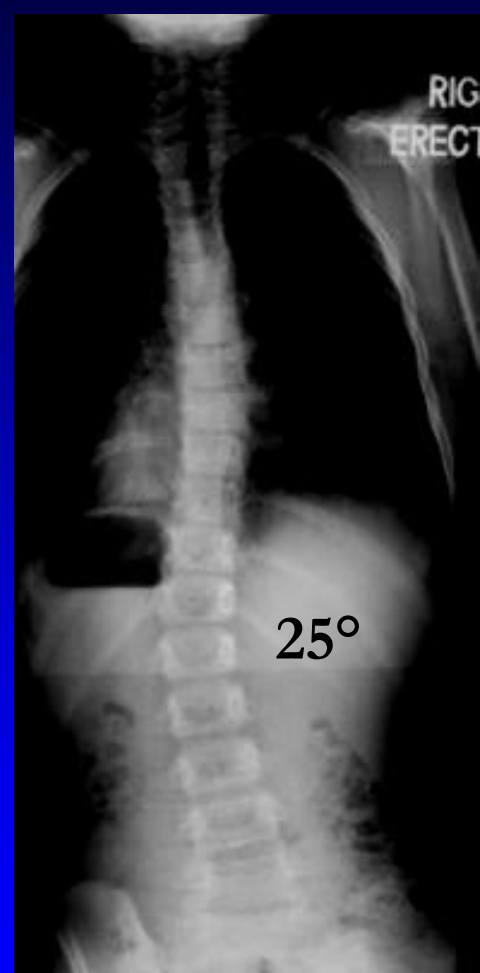Nov. 2002



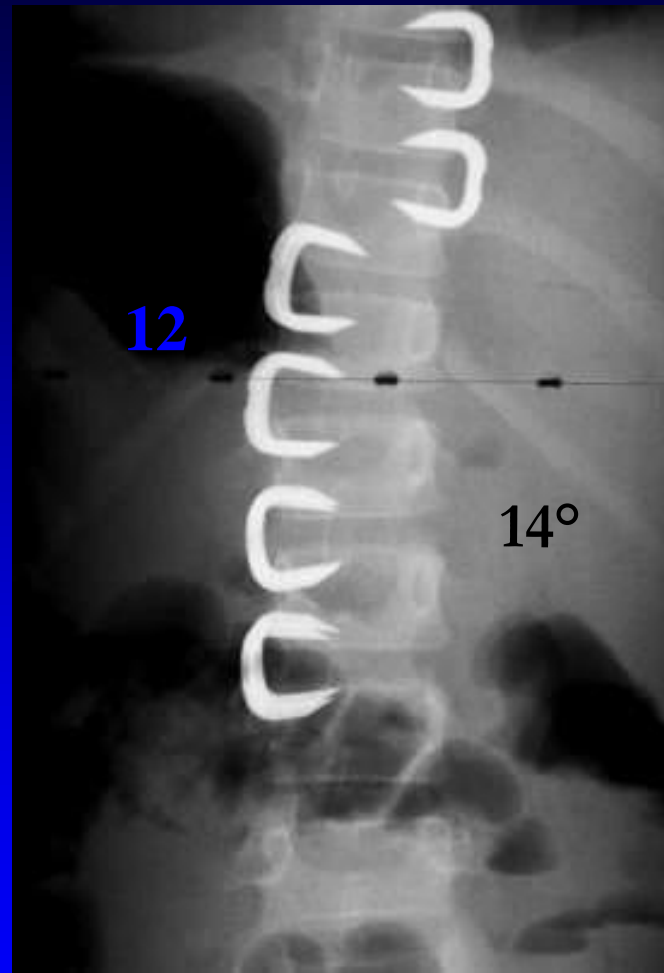
March 2005

Courtesy Randy Betz

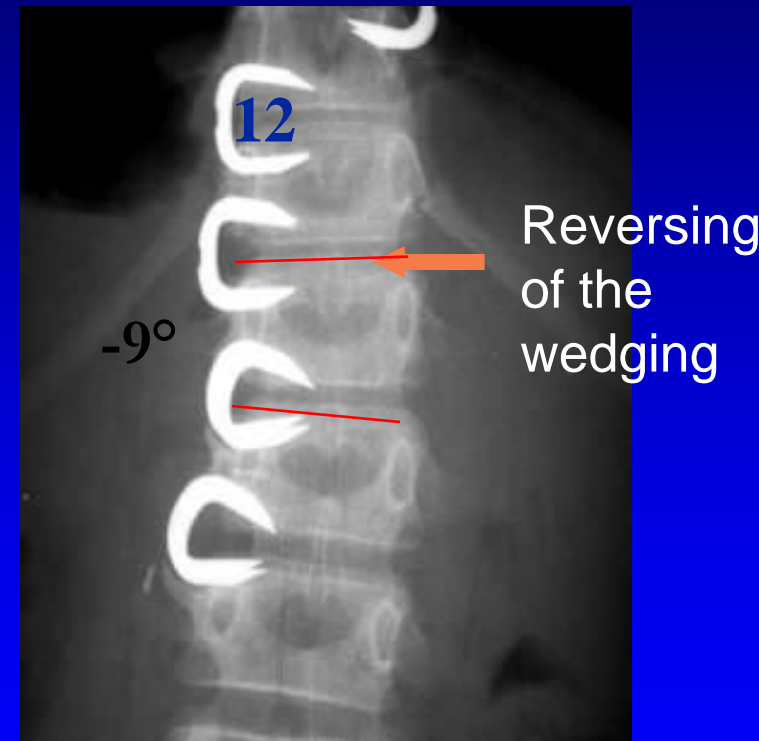
Growth Modulation \neq Natural History



10/ 2002



11/ 2002

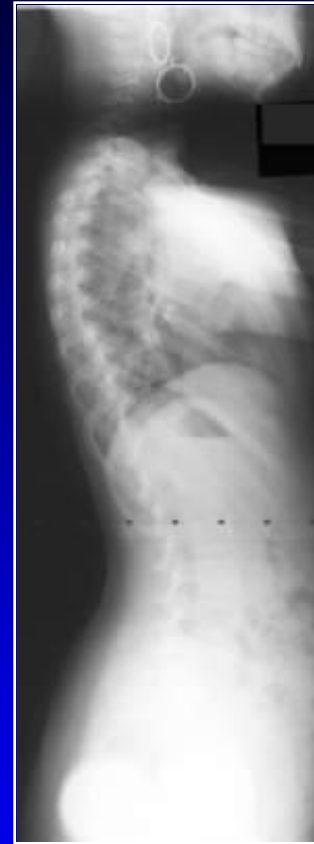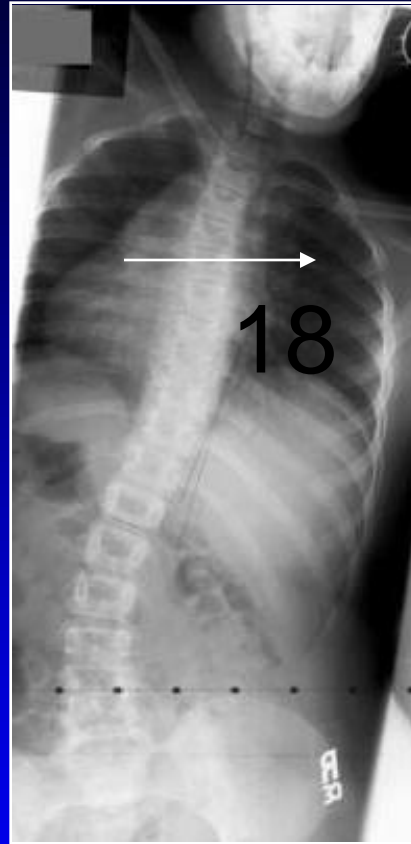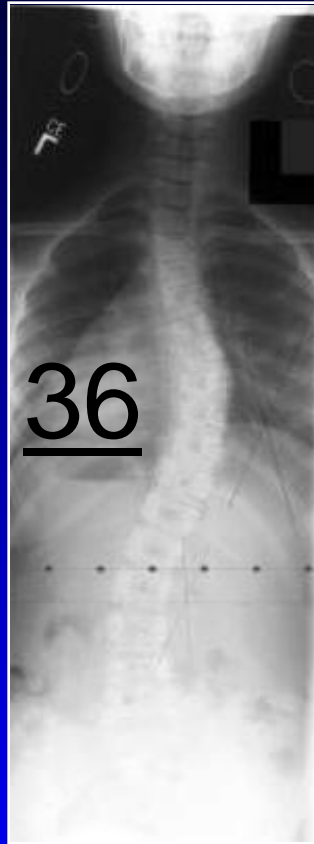


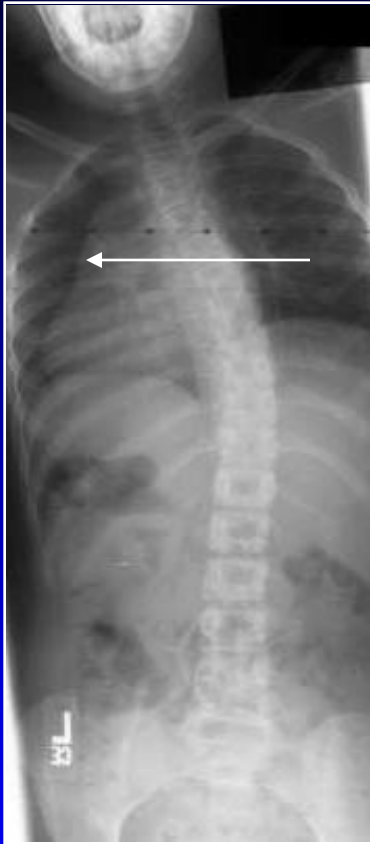2005

I'm intrigued

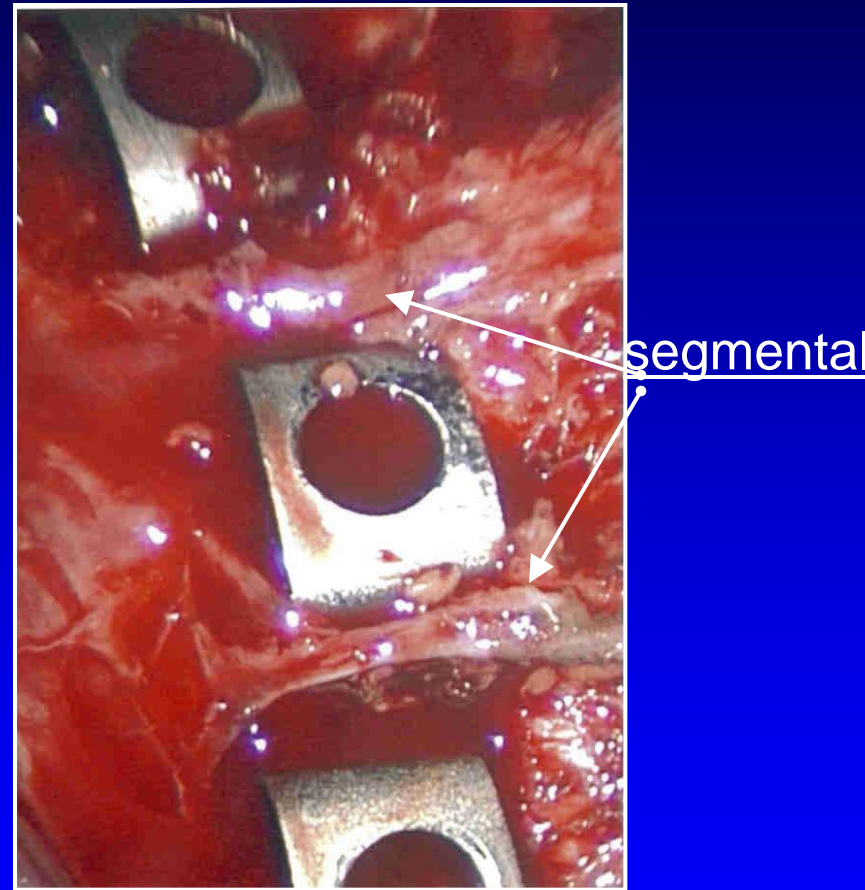
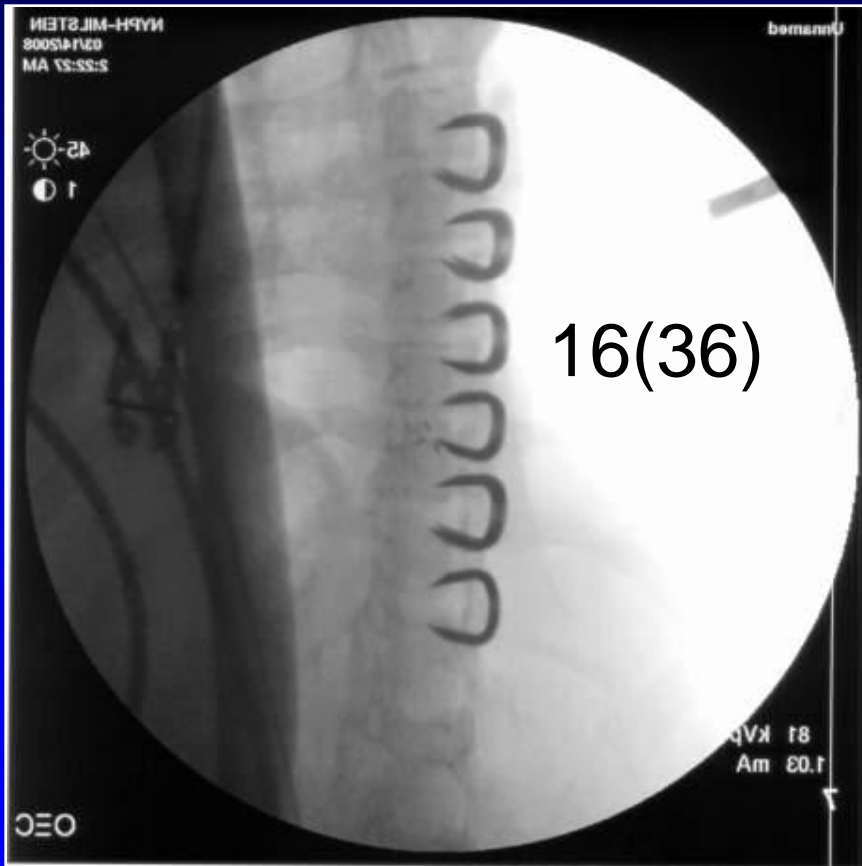
Courtesy Randy Betz

Caitlin – 8 yo



Despite bracing, $26^{\circ} \rightarrow 36^{\circ}$ in only 6 months
Progressive juvenile-onset scoliosis
Seizure disorder, mild speech delays

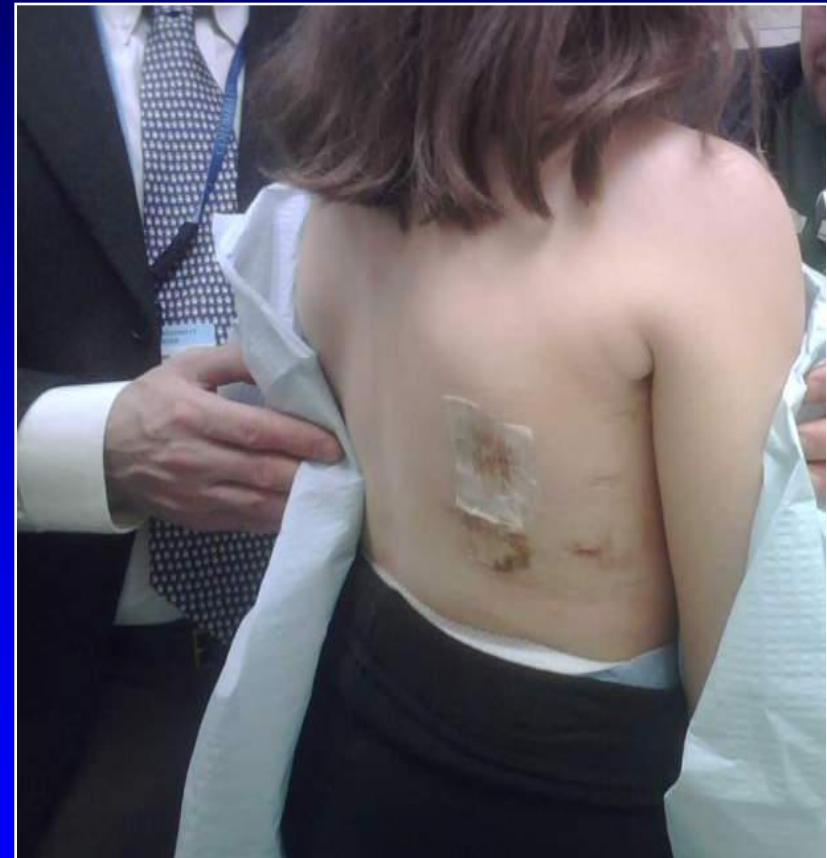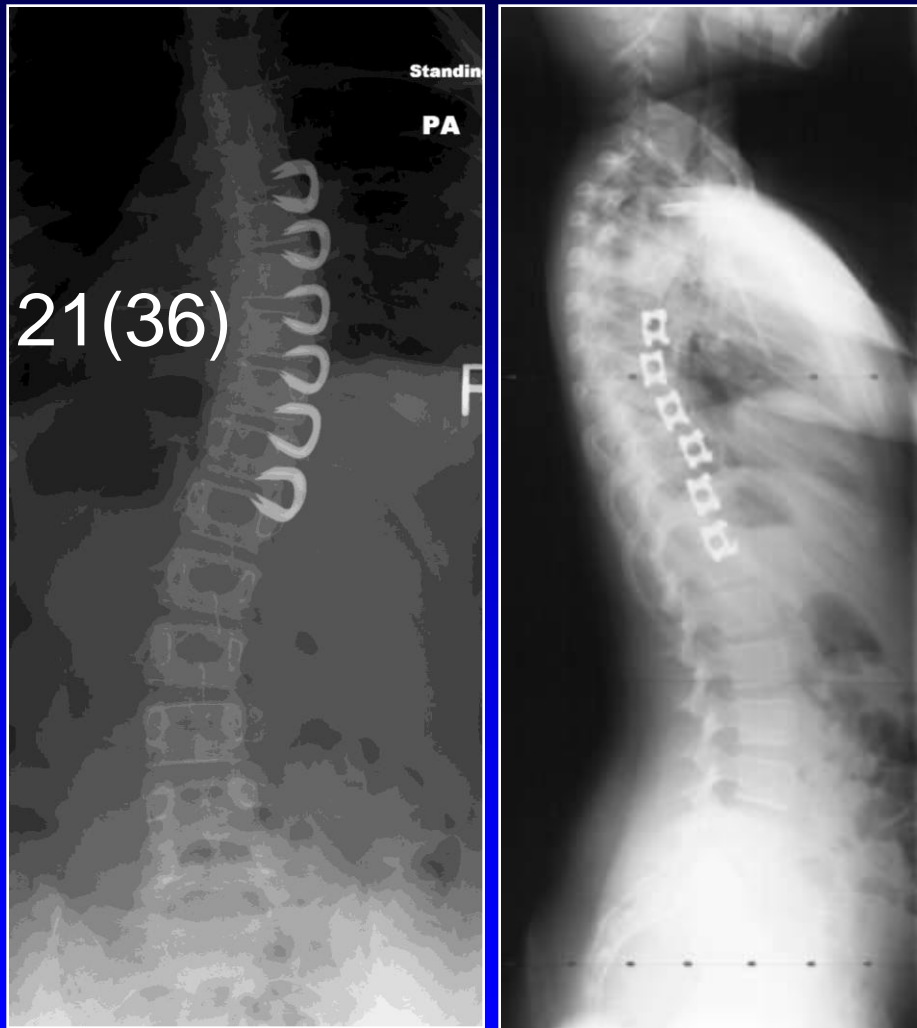Intraop Stapling



Correction on table

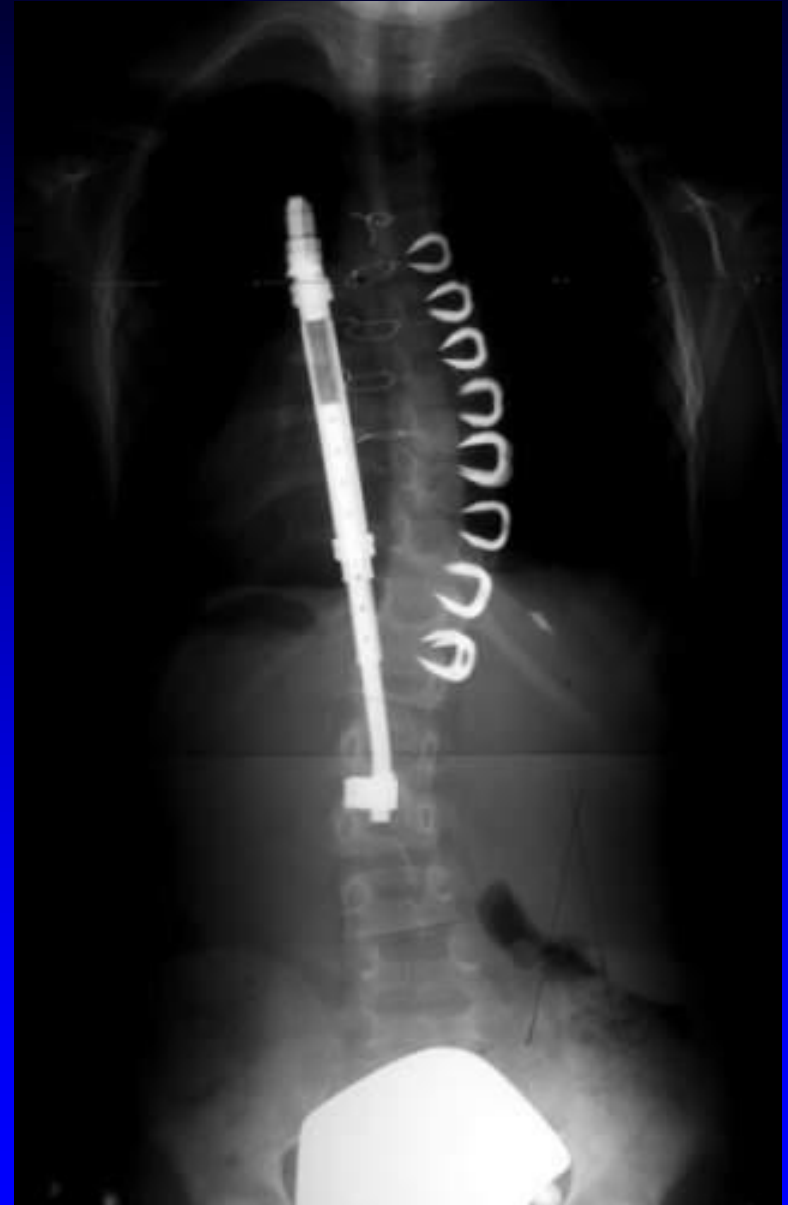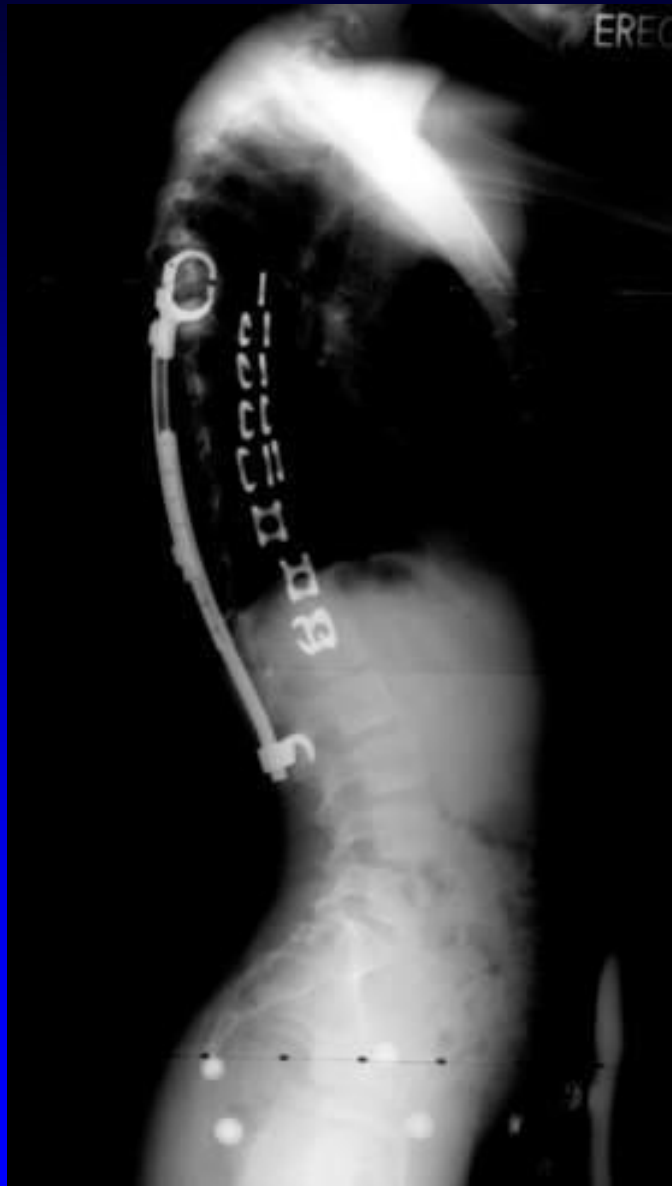I'm sold!

Anterior vertebral stapling, T6-T12



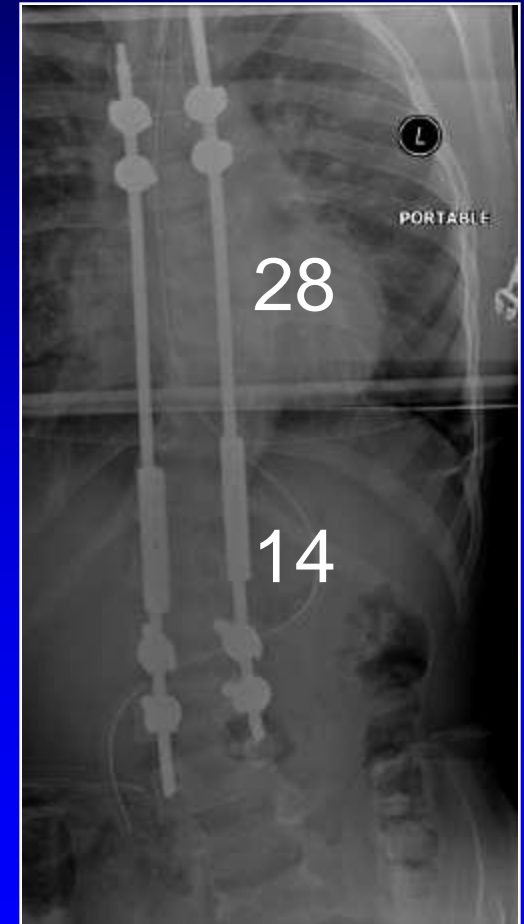
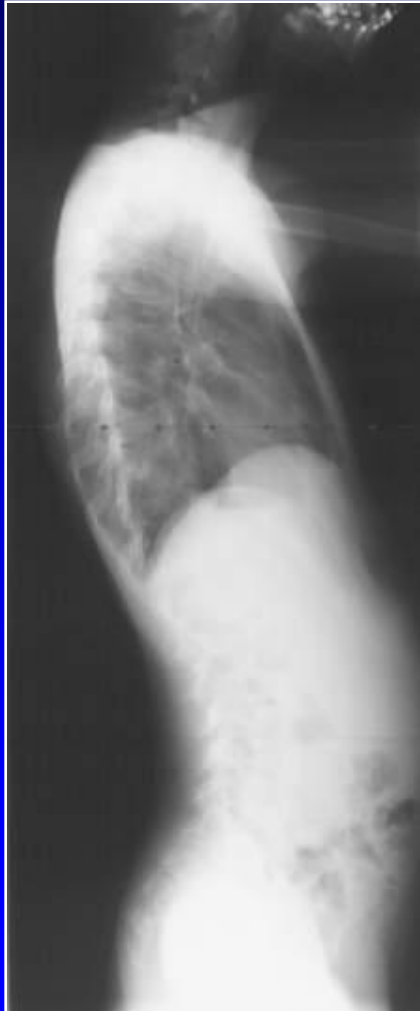
Nine days post op

Options for larger Curves – Hybrid Technique



Courtesy Randy Betz

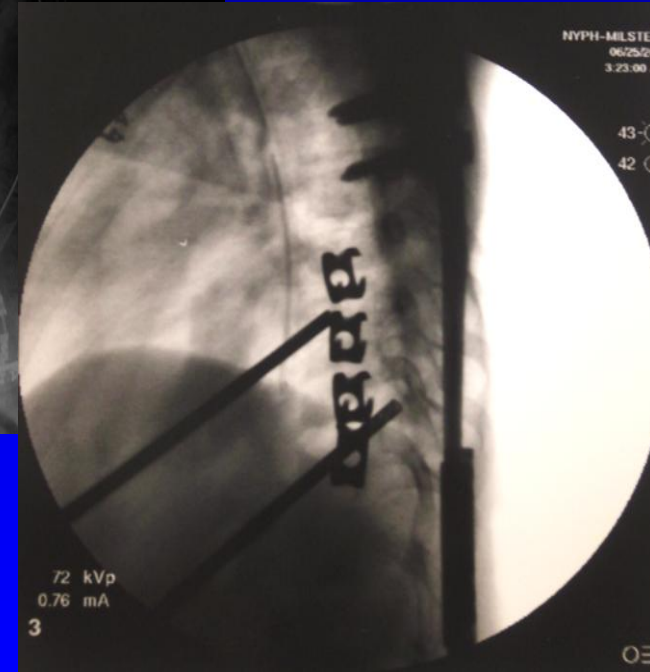
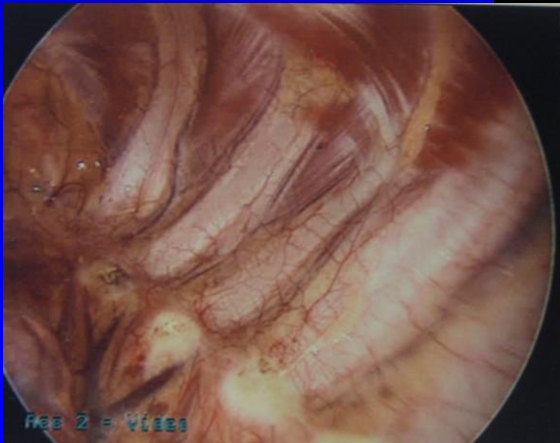
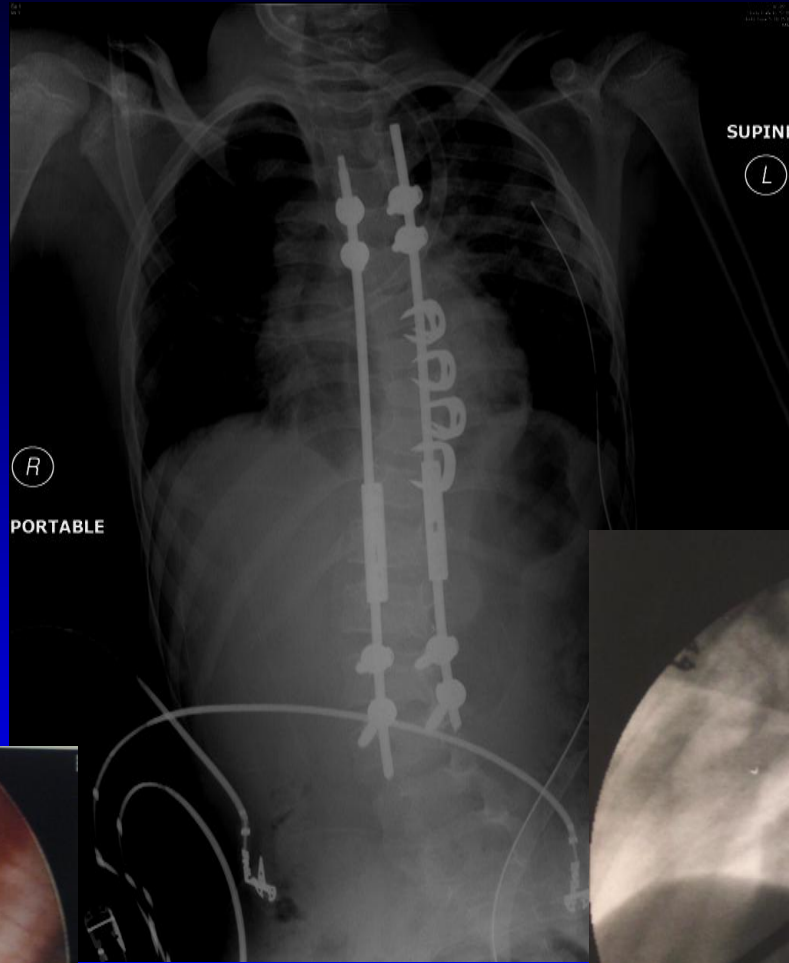
arthroplasty s/p growth rod...awaiting stapling



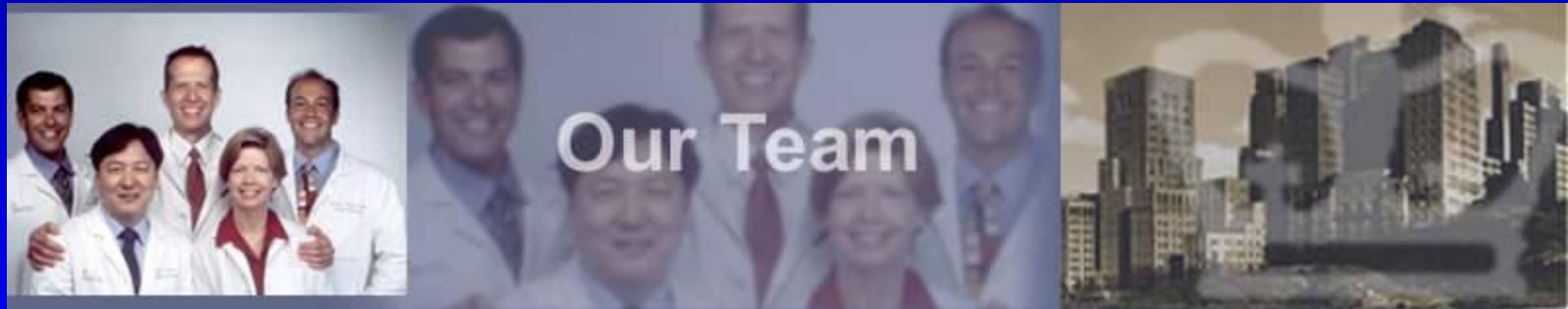
Early Onset Scoliosis

CASE :J.R.

- 11 yo M
- 6m post growing rods
- Anterior stapling -6/25/08



Thank You



mgv1@columbia.edu



Morgan Stanley
Children's Hospital of New York-Presbyterian
Columbia University Medical Center



Columbia Orthopaedics
Pediatric Orthopaedic Surgery